



Research Article

MODE OF ATTACHMENT OF *QUADRIACANTHUS* SPP. (MONOGENEA: DACTYLOGYRIDAE) TO THE GILLS OF THE NILE CATFISH *CLARIAS GARIEPINUS* AND THEIR LOCAL HISTOPATHOLOGICAL IMPACTS

M.M. EL-Naggar, M.I. Mashaly* and H.E. Allam

Department of Zoology, Faculty of Science, Mansoura University, Egypt, 35516

Article History: Received 9th January 2019; Accepted 1st February 2019; Published 11th February 2019

ABSTRACT

This is the first study on the mode of attachment and histopathological impacts of the monogeneans *Quadriacanthus* species. Most adult worms attach their haptor between two adjacent gill lamellae, others to the gill filaments (primary gill lamellae) particularly in the interlamellar spaces and a few attach to the top (distal) region of the gill lamella (secondary gill lamella). In all cases, hamuli, dorsal and ventral bars and marginal hooklets share in securing attachment. The posterior glandular system of *Quadriacanthus* spp. may play a significant role in attachment. Local histopathological changes of *Quadriacanthus* spp. include, compression of the gill lamellae, degeneration and rupture of the outermost pavement cells, breakdown of the wall of the blood spaces, fibrosis, necrosis, reduction and desquamation of the lamellar epithelial layers, loss of the innermost pavement cells, swelling and rupture of the blood cells and swelling and vaculation of the lamellar tissues at the site of hook insertion. The local host responses include proliferation of undifferentiated epithelial cells into M1 and M2 mucous cells, hyperplasia and appearance of lymphocytes at the site of haptor attachment.

Keywords: Attachment, *Clarias gariepinus*, *Quadriacanthus* spp., Monogenea, Histopathology.

INTRODUCTION

The Nile catfish, *Clarias gariepinus* Burchell, (syn. *C. lazera*), is one of the most important freshwater fish in Africa (Bishai & Khalil, 1997). Three *Quadriacanthus* species were recorded from the gills of *C. gariepinus* namely *Quadriacanthus aegypticus* El-Naggar & Serag, 1986, *Q. clariadis* Paperna, 1980 and *Q. kearni* El-Naggar & Serag, 1985. Among the monogenean parasites of *C. gariepinus*, *M. clarii* was the only species to have a particular attention in studying its mode of attachment and its local pathological impacts (Arafa *et al.*, 2009; El-Naggar *et al.*, 2016). Most studies on monogeneans of the genus *Quadriacanthus* Paperna, 1980 have been restricted to their morphological and anatomical structures (El-Naggar & Serag, 1985; El-Naggar & Serag, 1986; Francová *et al.*, 2017). The haptor of *Quadriacanthus* spp. is provided with two pairs of hamuli (dorsal and ventral) with their accessory sclerites, a ventral bar, a dorsal bar and seven pairs of marginal hooklets. It is not known whether or not

all of these sclerites participate in attachment of the haptor to the gills of the host. The present study would make it possible to compare the mode of attachment of *Quadriacanthus* spp. with that of other monogeneans found on the gills of the same host like *M. clarii* (see Arafa *et al.*, 2009) or with that of other monogeneans, like Cichlidyrids found on the gills of a different host as *Oreochromis niloticus* (see El-Naggar *et al.*, 2001). Several studies were done on impacts of the monogeneans on their microhabitats (Paperna, 1980; Arafa *et al.*, 2009; El-Naggar & Reda, 2003; El-Naggar *et al.*, 2001; El-Naggar *et al.*, 2016). These studies identified mortality in a wide variety of economically important fish in aquaculture systems (Amatyakul, 1972; Cone & Odense, 1984) but, little attention has been paid to study the impacts of monogeneans on the tissues of wild fishes. The present study is extended to illustrate the pathological impacts of *Quadriacanthus* spp. on the gill tissue of the Nile catfish *C. gariepinus* and their host responses.

*Corresponding Author: Dr. M. I. Mashaly, Department of Zoology, Faculty of Science, Mansoura University, Egypt, Email: dr.moh_mashaly@mans.edu.com, Mobile: 002-01004063132

MATERIALS AND METHODS

The specimens of *Clarias gariepinus* were caught from Manzala Lake, Demietta branch of the River Nile and Nawasa El-Gheit drain in Nile Delta, Egypt. Fishes were killed by a blow on the head and the gills were removed, placed in a Petri-dish containing filtered river water and searched for parasites with a stereomicroscope. The collected specimens of *Quadriacanthus* spp. (N=10) were studied using phase - contrast microscopy to illustrate detailed structures of the haptor. Gills with attached parasites (N=10) and those of uninfected hosts (control, N=10) were fixed in 10% formaldehyde for 2–8 hours, washed in distilled water, dehydrated in ethyl alcohol and embedded in paraffin wax. Longitudinal and transverse sections were cut at 5-8 μ m thickness, stained with haematoxylin and eosin, dehydrated in ethyl alcohol, cleared in xylene and mounted in Canada balsam. Stained sections were examined and photographed using Leitz Laborlux 20 EB research microscope provided with Omax digital camera. Preparation and examination of toluidine blue stained semi-thin sections of non-infested and infested gills of *C. gariepinus* were carried out according to the procedures made by Arafa *et al.*, (2009).

RESULTS

I- Normal gill structure of the catfish *Clarias gariepinus*:

Morphology of non-infested gills of *C. gariepinus* resembles that of other freshwater teleost fish species (Wilson & Laurent, 2002). The catfish *C. gariepinus* has four gill arches on each side. Each gill arch accommodates a single row of gill rakers on the dorsal side with respect to the body of the fish while the other side of the gill arch bears two hemibranches, each consisting of several parallel gill filaments (primary gill lamellae) from which arise perpendicularly two rows of gill lamellae (secondary gill lamellae), one on each side (Figure 1). There is a rigid mass of cartilaginous tissues in the core of each gill filament (Figure 1). The epithelium covering the gill filament is considerably thicker than that covering the gill lamellae, being composed of three or more cell layers (Figure 2). The filament surface is covered by cuboidal and squamous pavement cells (Figures 2, 4) while its internal boundary is lined with basal lamina (Figure 4). The space between the outermost pavement cells and the basal lamina is filled with numerous granular epithelial cells, some of which are considerably large and possess spherical nucleus and many fine cytoplasmic processes which interdigitate with the neighboring cells (C1), while others are smaller with spherical outline and large nucleus occupying most space of the cell (C2) (Figures 3, 4). Moreover, the epithelium of the gill filament contains two characteristic glandular types of cell (probably mucous cells), most of them are found close to the filament surface. The first kind of mucous cells (M1) is considerably large, oval-shaped and possesses a distinct rounded nucleus located at its base and lightly stained cytoplasm filled with numerous small granules (Figures 3, 4). The second kind of mucous cells (M2) has

densely stained cytoplasm which contains large granules (Figures 3, 4). However, in some toluidine blue -stained sections, large masses of granules are present in M2 cells (Figures 3, 4).

The epithelium covering the gill lamellae constitutes one-three layers of cells. The outermost layer consists of squamous and cuboidal pavement cells while the basal and intermediate layers are composed of large cells (C1) and small undifferentiated cells (C2) (Figure 4). Mucous cells of the gill lamellae are lesser in number than those found in the gill filament. The epithelium of the gill lamellae encloses blood spaces that are bounded by an endothelium with a thin basal lamina and surrounded externally by a layer of flattened pavement cells (Figures 3, 4). The blood spaces are supported by Pillar cells and contain erythrocytes and different types of leucocytes (Figures 3, 4).

II- Mode of attachment of *Quadriacanthus* spp. to the gills of *C. gariepinus*:

The body of *Quadriacanthus* spp. is flattened and elongated (Figure 5). The anterior end of the worm has at least two head lobes on each side used for temporary locomotion in conjunction with the main attachment organ, the haptor (Figure 5). Figure (6) shows the main sclerotized parts of the haptor of *Quadriacanthus aegypticus*, which include two pairs of hamuli (dorsal and ventral) with their accessory sclerites, one pair of bars (dorsal and ventral) and seven pairs of marginal hooklets. Examination of living specimens using phase contrast microscopy has revealed that the marginal hooklets I, II, V, VI and VII project from the ventral surface of the haptor, while hooklets III and IV project from its dorsal surface. In most specimens examined with stereomicroscopy, adult worms of *Quadriacanthus* spp. were seen attached by their haptor between two adjacent gill lamellae (Fig. 7) while others were seen attached directly to the gill filament tissues. In few cases, some parasites were seen attached to the top of the gill lamellae. In most sections examined, the pointed hooked regions and sometimes part of the shaft of both ventral and dorsal hamuli were seen inserted into the tissues of the gill filaments and/or gill lamellae (Figures 7, 9, 13, 14). In transverse sections, the pointed hooked region of each hamulus is ensheathed by a sleeve cavity containing homogeneous fine secretion (Figures 13, 14). In many sections, there was evidence of insertion of the marginal hooklets (Figures 7, 12) into the gill tissues. During attachment, the terminal parts of dorsal and ventral bars project with their covering tissues over the surface of the haptor and come into close contact with the covering epithelium of the gill filaments and lamellae (Figures 8, 11).

III-Local impacts of *Quadriacanthus* monogenean species and their host response:

At the site of attachment, between two neighboring gill lamellae, a considerably deep, cup-shaped depression is formed around the posterior attachment organ of the worm (the haptor) (Figs. 7, 8). Consequently, the neighboring gill

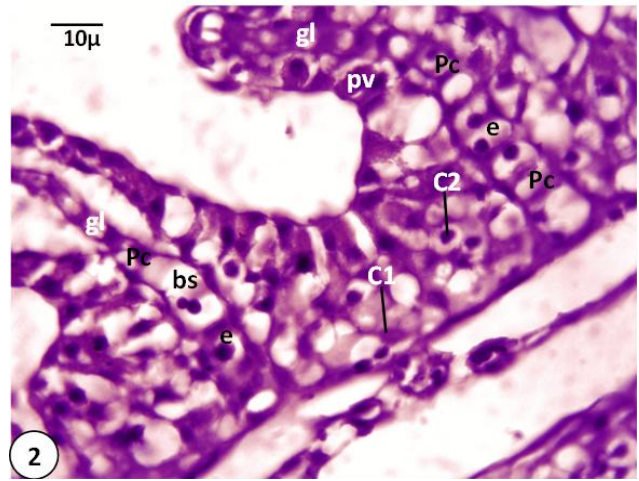
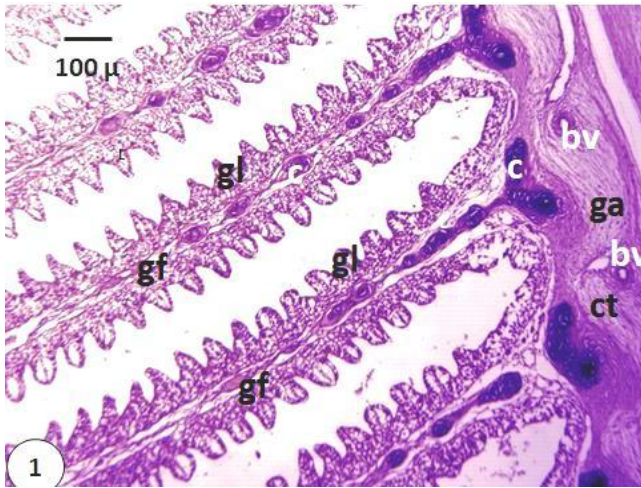


Figure 1. Photomicrograph of section stained with haematoxylin and eosin of normal gill filaments (gf) and gill lamella (gl). bv, Blood vessel; c, cartilaginous tissues; ct, connective tissues; ga, gill arch. Scale bar =100μm.

Figure 2. Photomicrograph of section stained with haematoxylin and eosin of magnified part of normal gill lamella (gl) showing that gill epithelium is covered externally by pavement cells (pv). Note two types of cells: large cells (C1) and small cells (C2). Note that, blood space (bs) is supported by Pillar cells (Pc) and erythrocytes (e). Scale bar =10μm.

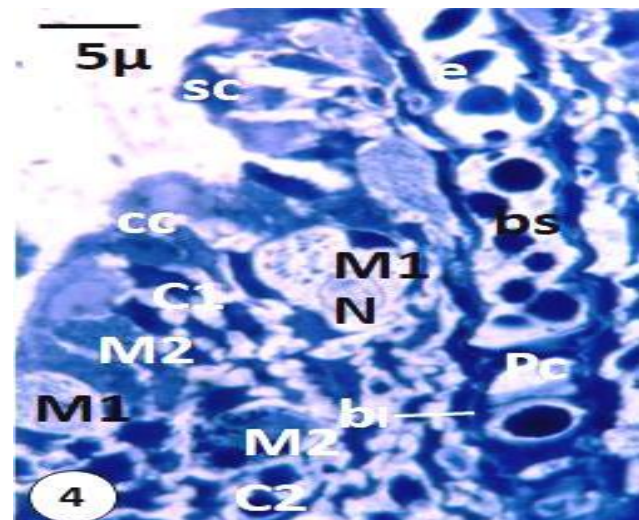
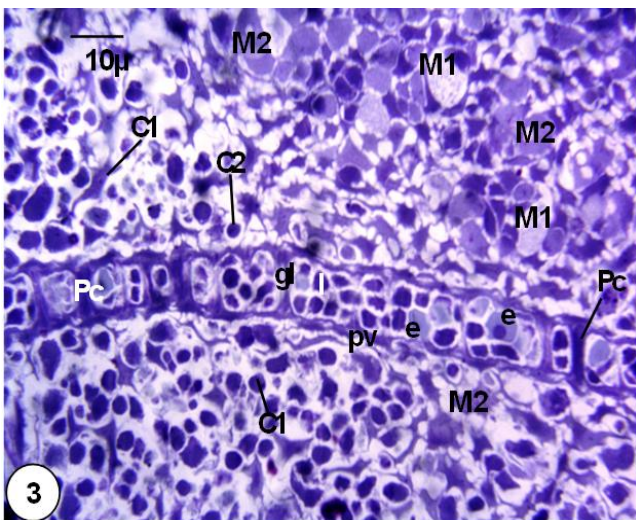


Figure 3. Photomicrograph of toluidine blue-stained section showing normal gill lamella (gl) and interlamellar space. C1, Large epithelial cell; C2; small undifferentiated epithelial cell; e, erythrocyte; l, lymphocyte; M1, mucous cell with small granules; M2, mucous cell with large granules; Pc, Pillar cell; pv, pavement cell. Scale bar =10 μm.

Figure 4. Photomicrograph of toluidine blue-stained section of magnified part of normal gill lamella and interlamellar region. Note that outermost layer consists of squamous (sc) and cuboidal (cc) pavement cells. Also, there are two types of mucous cells, M1 with small granules and M2 with large densely-stained granules. bl, Basal lamina; bs, blood space; N, nucleus. Other abbreviations as in Fig. 3. Scale bar =5 μm.

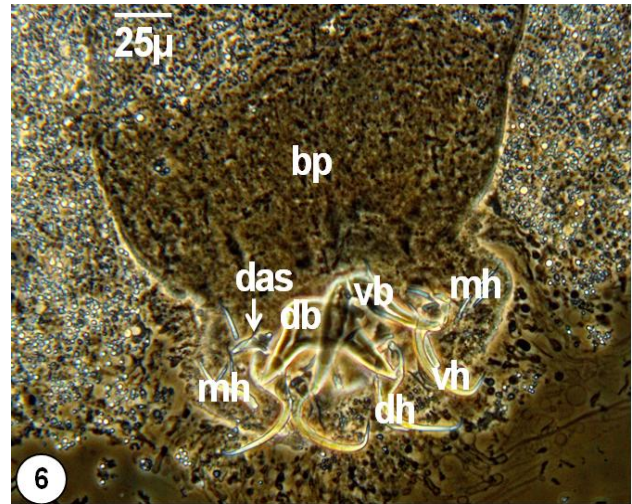
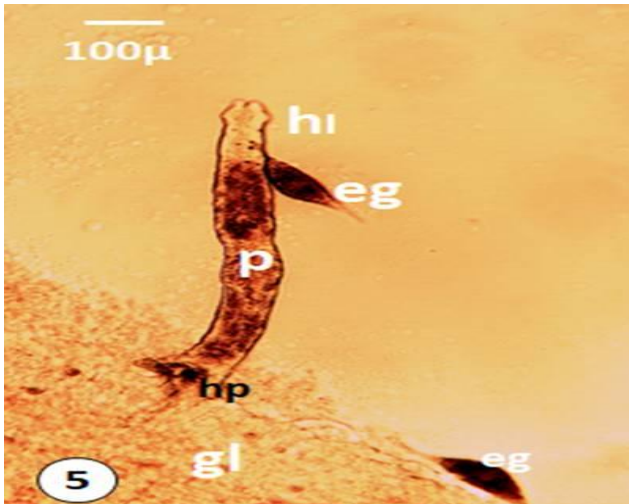


Figure 5. Light microscope photomicrograph of flattened living *Quadriacanthus* parasite (p) attached with its haptor (hp) to the gill lamellae (gl) of the host. eg, Egg; hl, head lobes. Scale bar =100 μm.

Figure 6. Phase-contrast photomicrograph showing sclerotized parts of haptor of *Quadriacanthus aegypticus*, which include one pair of dorsal hamuli (dh) , one pair of ventral hamuli (vh), ventral bar (vb), dorsal bar (db) and 7 pairs of marginal hooklets (mh). bp, Body prober; das, dorsal accessory sclerite. Scale bar =25 μm.

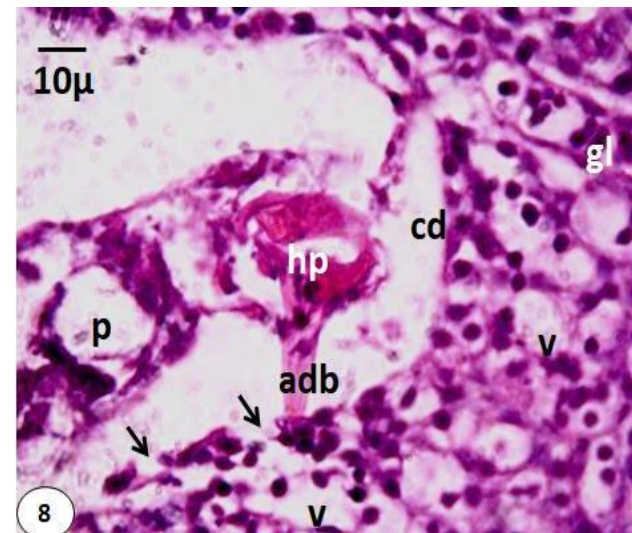
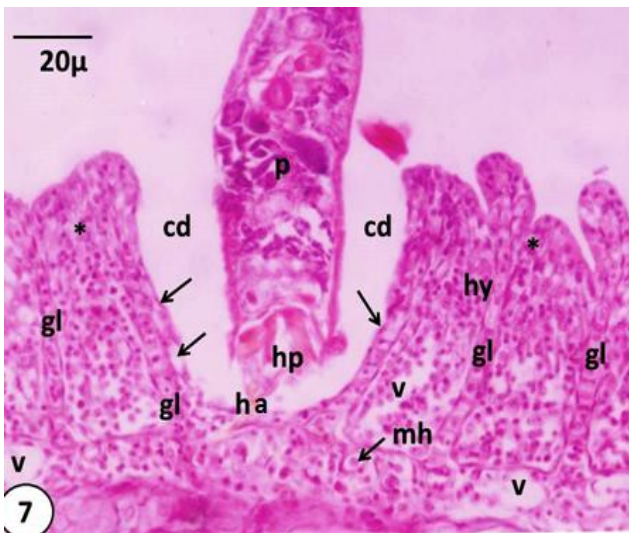


Figure 7. Photomicrograph of longitudinal section stained with haematoxylin and eosin of the parasite attached with haptor (hp) between two gill lamella (gl) using the hamulus (ha) and marginal hooklets (mh) and produces a cup-shaped depression (cd), compression of the neighboring gill lamella, fusion of terminal portions of gill lamellae (*), hyperplasia (hy), vacuolation (v) and rupture and degeneration of the gill epithelium (arrows). Scale bar =20 μm.

Figure 8. Photomicrograph of the haptor (hp) of parasite (p) attached to interlamellar region stained with haematoxylin and eosin. Note the insertion of terminal portion of the lateral arm of the dorsal bar (adb) into gill tissue. Note also rupture of the outer most layer of the gill epithelium (arrows). cd, Cup-shaped depression; gl, gill lamella; v, vacuolation. Scale bar=10 μm.

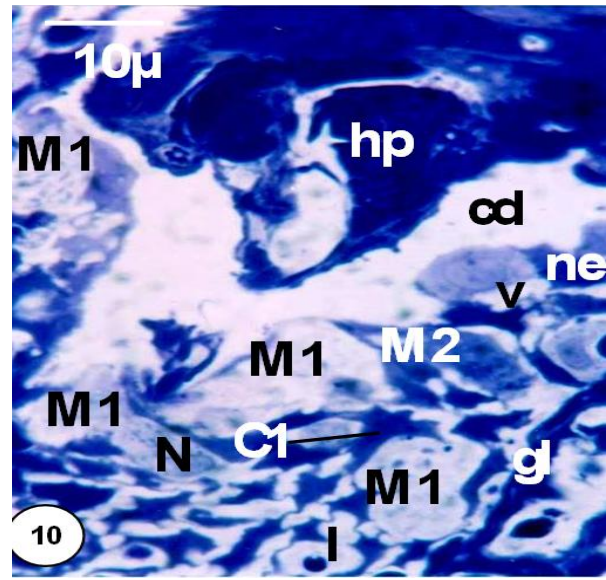
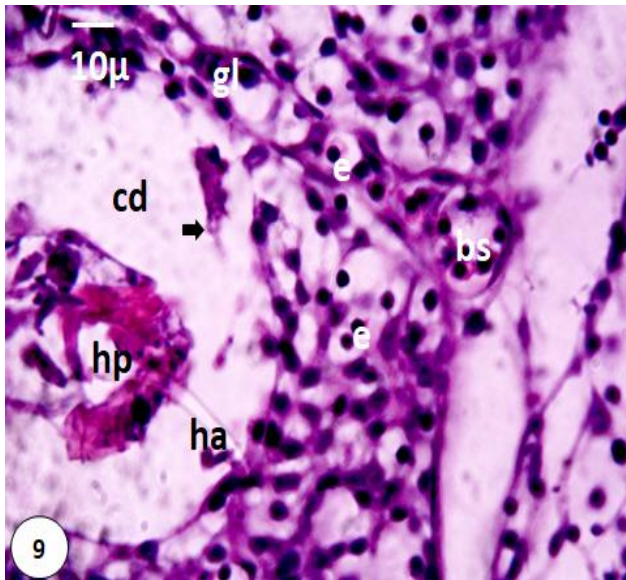


Figure 9. Photomicrograph of section stained with haematoxylin and eosin showing haptor (hp) of the parasite (p) attached to the interlamellar region. Note insertion of the pointed hooked region of the hamulus (ha) into the gill tissue and rupture of the gill epithelium (thick arrow). bs, Blood space; cd, cup-shaped depression; e, erythrocyte; gl, gill lamella. Scale bar =10 µm.

Figure 10. Photomicrograph of toluidine blue-stained section showing part of the haptor (hp) attached to the gill tissue. Note the increased number of mucous cells (M1 and M2) at attachment site. Note also the presence of some lymphocytes (l), necrosis (ne) and vaculation (v) in gill epithelium. cd, Cup-shaped depression; gl, gill lamella; N, Nucleus. Scale bar= 10 µm.

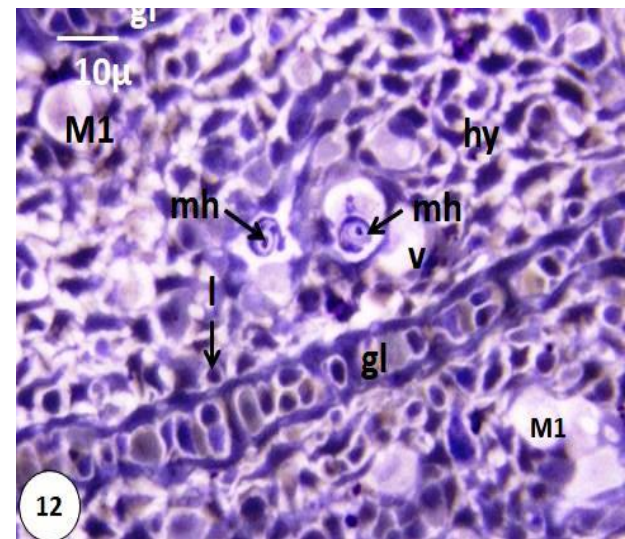
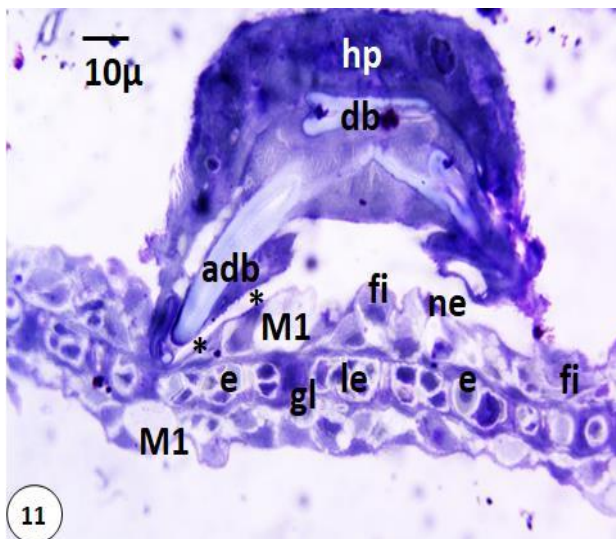


Figure 11. Photomicrograph of toluidine blue-stained sections showing haptor (hp) of the parasite closely attached to gill tissue of the host. Note that the terminal portion of dorsal bar arm creates a long groove (*) in the gill epithelium and breakdown of the endothelium covering blood space (bs) leading to compression of erythrocytes (e) and leucocytes (le). Note also necrosis (ne) and fibrosis (fi) of the gill epithelial cells. M1, Mucous cell with small granules. Scale bar =10 µm.

Figure 12. Photomicrograph of toluidine blue-stained sections showing insertion of the marginal hooklets (mh) into gill lamellae (gl). Note increased number of mucous cells (M1), hyperplasia (hy), lymphocytes (l) and vaculation in the interlamellar tissue between the gill lamella (gl). Scale bar=10 µm.

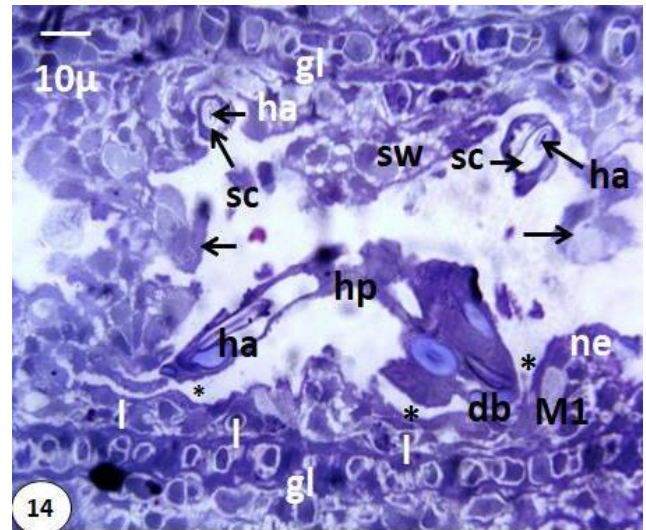
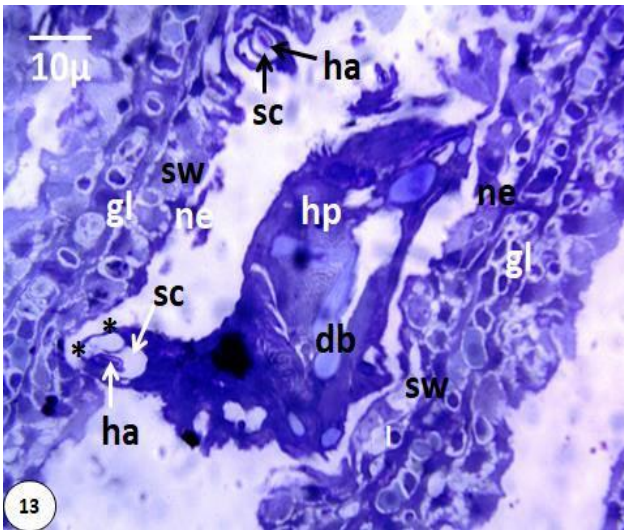


Figure 13. Photomicrograph of transverse section stained with toluidine blue of the haptor (hp) attached between two adjacent gill lamella (gl). Note that each hamulus (ha) is bounded by a sleeve cavity (sc) filled with homogeneous secretion and creates a groove (*) in the gill epithelium. db, Dorsal bar; ne, necrosis; sw, swelling. Scale bar=10 μm.

Figure 14. Photomicrograph of sclerotized parts of the haptor (hp) penetrating the gill lamellae (gl) stained with toluidine blue. Hamuli (ha) and bars (db) create conspicuous grooves (*) and cause swelling (sw), necrosis (ne) and rupture of the gill tissue (arrows). Each hamulus (ha) is ensheathed by a sleeve cavity (sc) containing homogeneous material. Numerous lymphocytes (l) are present at attachment site. M1, mucous cells with small granules. Scale bar=10 μm.

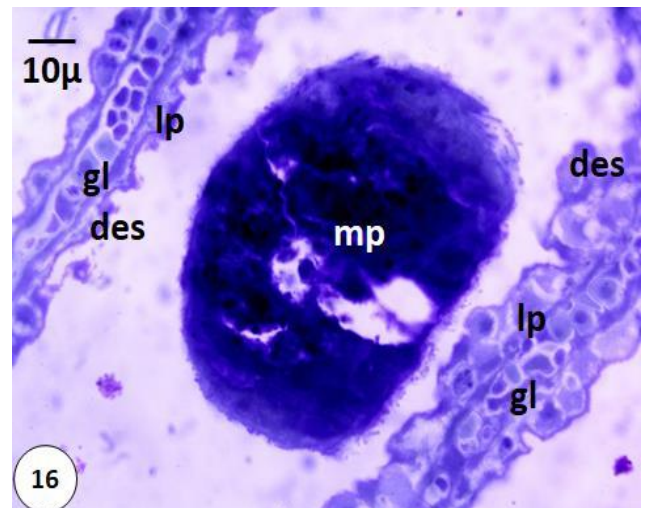
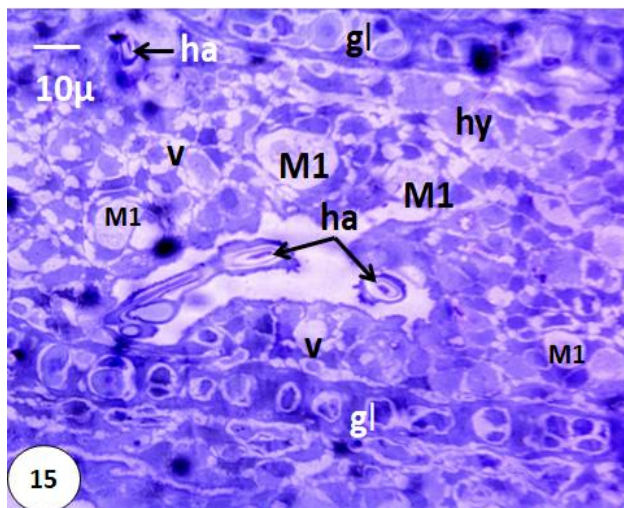


Figure 15. Photomicrograph of toluidine blue-stained section of the hamuli (ha) inserted in the interlamellar tissue of the host. Note hyperplasia (hy), vaculation (v) and increased number of mucous cells (M1). gl, Gill lamella. Scale bar=10 μm.

Figure 16. Toluidine blue-stained, transverse section of middle region of the parasite (mp) and adjacent gill lamella (gl). Note that the lamellar epithelium (lp) becomes thinner (1-2 layers) and desquamation (des) of its outer surface is apparent. Scale bar=10 μm.

lamellae with their epithelial cells appear in abnormal position and condition where they become more compressed and closer to each other (Figure 7). In many cases, the terminal portions of the gill lamellae fuse with each other so that the epithelial contents of each lamella become in continuity with that of other lamellae (Figure 7). The outer surface of the host tissue lining the depression showed degeneration and rupture of the outermost pavement cells (Figure 7-9). Also, fibrosis (Figure 11) and necrosis (Figure 10, 14) are clearly seen at the host parasite interface. In sections, particularly at the level of the middle region of attached parasite, between the two neighboring gill lamellae, the lamellar epithelium is reduced to only one or two layers and showed desquamation (Figure 16). Toluidine blue - stained sections have revealed that the terminal portions of the arms of the ventral and dorsal bars elevate above the level of the haptor surface and press on the facing lamellar epithelium creating conspicuous grooves that reach as far as the endothelium coating the blood spaces (Figure 11). As a result of this pressure, the pavement cells are lost. Moreover, the wall of the blood spaces squeezes and becomes thinner and the cells inside appear more compressed and lost their normal appearance (Figure 11). This is clearly visible in the swelling and rupture of the erythrocytes that lost their integrated structure particularly their nuclei (Figure 11). The ventral and dorsal hamuli as well as the marginal hooklets protruding and projecting from the haptor surfaces produce characteristic impacts as they proceed inside the tissue of the host. These impacts include formation of a depression inside the lamellar epithelium and damage and rupture of the surrounding epithelial cells (Figure 14). Insertion of the pointed hooked regions of the hamuli and marginal hooklets cause perforation, swelling and vaculation in the gill tissues (Figure 12, 14). The most characteristic feature of the host responses against infestation with *Quadriacanthus* spp. is the proliferation of undifferentiated epithelial cells into numerous M1 (Figure 15) and M2 (Figure 10) mucous cells particularly in the lamellar and interlamellar epithelium facing the worm haptor. However, the mucous cells in the interlamellar epithelium are more numerous than those of the lamellar epithelium. Also, these mucous cells appear in the region of interlamellar epithelium not infected with the worm but lie in the nearest region. Some lymphocytes were detected at the site of insertion of the hamuli and marginal hooks (Figures 10, 12, 14) and also at the site of contact between the terminal portions of the dorsal and ventral bars and host tissue (Figures 13, 14). Hyperplasia of the gill tissue is clearly visible at the site of attachment of the hamuli, bars and marginal hooklets (Figures 7, 12, 15).

DISCUSSION

This is the first study describing the mode of attachment and histopathological impacts of the monogeneans *Quadriacanthus* spp. to the gills of the catfish *Clarias gariepinus*. The majority of adult worms insert their haptor in-between two adjacent gill lamellae, others attach directly to the gill filament particularly in the interlamellar spaces

and a few parasites attach to the top (distal) part of the gill lamella. The hamuli, dorsal and ventral bars and marginal hooklets share in securing attachment. The pointed hooked regions of the dorsal and ventral hamuli as well as the blades of marginal hooklets insert into the gill tissues whereas the terminal pointed regions of both ventral and dorsal bars elevate above the haptor surface and rely on the gill tissues. The mode of attachment of *Quadriacanthus* spp. generally resembles that of other monogeneans possessing the same pattern of haptor sclerites (Molnár, 1972; Ramadan *et al.*, 1995).

There was a conflict concerning the role of marginal hooklets in attachment. Some authors, (Lester, 1972; Molnár, 1972, Cone & Odense, 1984; Ramadan *et al.*, 1995) found that the marginal hooklets play a significant role in attachment while others (Arafa *et al.*, 2009; El-Naggar *et al.*, 2001; El-Naggar *et al.*, 2016) reported that no role for the marginal hooklets of *Cichlidogyrus* spp. and *Macrogyrodactylus clarii*. In these studies, the hamuli were the only haptor sclerites sharing in attachment. In the present study, the pointed hooked region of each hamulus is sheathed by a sleeve cavity containing homologous fine secretion. El-Naggar and Kearns (1989) demonstrated hamulus glands with their secretion coming out through a tubular sleeve around the hooked region of the hamuli of *Cichlidogyrus halli*. They suggested that the secretion bathes the naked pointed region of the hamuli as they penetrate deeply into the gill tissue and thus reduces or eliminates the gill resistance by softening the gill tissue in the path of the inserted hooks. This may reduce the muscular effort needed to push the hamuli into the gill (El-Naggar & Kearns, 1989).

The most characteristic feature differentiating *Quadriacanthus* spp. from other closely related monopisthocotyleans is the insertion of the blades of marginal hooklets into the gill tissues of the host during attachment. Kearns (1998) suggested that the marginal hooklets of the monogenean parasites play minor contribution during the process of attachment if compared with the hamuli. El-Naggar *et al.* (2001) found no evidence of insertion of the marginal hooklets of *Cichlidogyrus* spp. during attachment. Arafa *et al.* (2009) and El-Naggar *et al.* (2016) found no participation of the marginal hooklets in attachment of the gyrodactylid *M. clarii*. However, Arafa *et al.* (2003) reported a superficial insertion of some marginal hooklets of *M. congolensis*. The mode of attachment of *Quadriacanthus* spp. acquires its significance from the fact that all the haptor sclerites contribute in securing a firm attachment against the strong gill ventilating water current. Harris (1983) suggested that the marginal hooklets may prevent the hamuli of the oviparous gyrodactylid *Oogyrodactylus farlowellae* from turning about their longitudinal axis and tearing free of the host skin of the catfish *Farlowella amazonum*. In *Quadriacanthus aegypticus*, El-Naggar and Serag (1986) described prehaptor glands with their ducts extending into the haptor where some of them form two large reservoirs

close to the hamuli and others could not be traced. This glandular system of *Q. aegypticus* may play a significant role in attachment. In the present study, each hamulus is bounded by a sleeve cavity filled with homogeneous secretion which may be a product of the prehaptor glands. Therefore, the haptor glands of *Quadriacanthus* spp. may play an important role together with the hamuli and marginal hooklets in firm attachment to the host gills. Similar haptor glands were described in *C. halli* by El-Naggar and Kearn (1989) who suggested that the haptor gland secretion provide temporary adhesion during leech-like movement of the worm and this may reduce the risk of dislodgment of the haptor by the host's gill ventilating water current.

A unique mode of attachment was demonstrated in the viviparous skin parasite *M. congolensis* (Arafa *et al.*, 2009) and in the gill parasite *M. clarii* (Arafa *et al.*, 2009; El-Naggar *et al.*, 2016) parasitizing the catfish *C. gariepinus*. The footprints of the haptor of *M. congolensis* and *M. clarii* were elevated above the general surface of the host gills, bounded by clefts produced by the anterior, lateral and posterior muscular flaps of the haptor. The authors suggested that *M. congolensis* and *M. clarii* use suction during haptor attachment. There is no evidence in the present study of suction mechanism in *Quadriacanthus* spp. and further investigations using scanning and transmission electron microscopes are still needed in this field to clarify precisely the mechanism of attachment in these parasites.

In the present study, local histopathological changes created by attachment of the haptor of *Quadriacanthus* spp. to the gill tissues of the catfish *C. gariepinus* include: compression of the gill lamellae, degeneration and rupture of the outermost pavement cells, breakdown of the wall of blood spaces, fibrosis and necrosis, reduction and desquamation of the lamellar epithelial layers, loss of the innermost pavement cells, swelling and rupture of the blood cells and swelling and vaculation of the lamellar tissues at the site of hook insertion. The local histopathological changes of *Quadriacanthus* spp. closely resemble those produced by other monogeneans (El-Naggar *et al.*, 2001; Arafa *et al.*, 2009; El-Naggar *et al.*, 2016). Generally, the histopathological changes produced by *Quadriacanthus* species might interfere with the normal respiratory functions and subsequently lead to an impairment of the general health condition of the fish (Schwaiger *et al.*, 2004). The most characteristic feature of *Quadriacanthus* species is that the parasite produces a cup-shaped depression in the gill lamella at the site of attachment. Similar depressions were reported around the haptor of other monogenans (Amatyakul, 1972; Ramadan *et al.*, 1995). El-Naggar *et al.*, (2001) suggested that the pressure exerted by the parasite in the form of body weight and muscular action might help in the formation of this depression.

The breakdown of the wall of blood spaces including Pillar cells and loss of the innermost pavement cells may increase the blood flow inside the lamella causing dilatation of the marginal channel, blood congestion or even an

aneurism (Camargo & Martinez, 2007; Rosety-Rodríguez *et al.*, 2002). Degeneration of Pillar cells and blood corpuscles was reported in the gill lamellae of *Oreochromis niloticus* infected with *Cichlidogyrus* spp. (El-Naggar *et al.*, 2001). This degeneration decreases the gas exchange capacity of the gill lamellae. Necrosis, fibrosis and reduction in the layers of lamellar epithelium of *C. gariepinus* will subsequently decrease the surface area of the gill tissues available for respiration and osmoregulation activities. As in *Quadriacanthus* spp., Piasecki *et al.* (2004) reported that some of the species of *Quadriacanthus* are potentially pathogenic and morbid infections with unidentified species were reported from farmed catfish *Clarias batrachus* in Southeast. Arafa *et al.* (2009) demonstrated that *M. clarii* causes some lesions at the site of attachment including dysfunction and fusion of the gill lamellae, infiltration of erythrocytes and degeneration and fibrosis of the interlamellar epithelium. Hirazawa *et al.* (2016) recorded a significant decrease in the hematological parameters, hematocrit, blood urea nitrogen, and total protein and globulin values in *Seriola dumerili* severely infected with *Neobenedeniagirellae*. Moreover, the epidermis becomes significantly thinner and this may lead to disruption in the osmotic balance of the host fish and impairment of the liver and kidney function.

Resistance against monogeneans is partly associated with host mucus secretion, which may form a protective sheath against the invasion of ectoparasites (Evans & Gratzek, 1989). In the present study, the host response against infestation with *Quadriacanthus* species include proliferation of undifferentiated epithelial cells into M1 and M2 mucous cells, and appearance of lymphocytes in the host tissues at the site of haptor attachment. In this respect, *Quadriacanthus* species resemble other monogeneans (El-Naggar *et al.*, 2001 & 2016). Accumulation of mucous cells at the site of infection was also recorded in the gill tissues of grass carp infected with *Dactylogyrus lamellatus* (Molnár, 1972), but Paperna (1980) showed no obvious change in the number of mucous cells as a result of infection of *Scomber australasicus* with *Didymozoid* trematodes. In contrast, a decrease in the number of mucous cells was reported in the epidermis of *Lates calcarifer* infected with *Neobenedenia* sp. (Trujillo *et al.*, 2015). The function of mucus is not fully understood. However, cutaneous mucus, secreted by mucous cells present in the epidermis, is an important component of teleost immune responses and it is considered to be the first line of defense against infection through skin epidermis (Zhao *et al.*, 2008). There is evidence indicating that it forms a protective sheath against the invasion of ectoparasites (Spotte, 1970).

In the present study, hyperplasia was observed at the site of attachment in the lamellar and interlamellar tissues. Similar response was recorded in the kingfish *Seriola lalandi*, heavily infested with *Zeuxapta seriola* (Mansell *et al.*, 2005), as well as in the cichlid *Oreochromis niloticus* infested with *Cichlidogyrus sclerosus*. Arafa *et al.* (2009) and Pahor-Filho *et al.* (2017) recorded epithelium

detachment and severe hyperplasia in the gill tissues of mullets by the monogenean *Ligophorus uruguayense*. El-Naggar *et al.* (2001) suggested that hyperplasia may entangle attached monogenean parasite, protect the underlying tissues against pathogenic organisms and/or replace degenerated tissues by new healthy ones. Appearance of lymphocytes at the site of attachment of *Quadriacanthus* spp. is a good indication of host response towards the pathogens and lymphocytes may serve as phagocytes.

CONCLUSION

The monogeneans *Quadriacanthus* species use all their haptor sclerites in securing attachment between adjacent gill lamella or to the gill filaments of *C. gariepinus*. They cause serious histopathological changes like degeneration and rupture of the pavement cells, breakdown of the blood spaces, fibrosis, necrosis, reduction and desquamation of the gill epithelium, swelling and vaculation of the lamellar tissues at attachment site. Further studies using transmission and scanning electron microscopy are needed in order to have a complete understanding of the haptor musculature and subsequently the role of each sclerite in attachment.

ACKNOWLEDGMENT

This research is part of a project supported by a grant offered to Miss Hend Allam from the Academy of Scientific Research and Technology in Egypt.

REFERENCES

- Amatyakul, C. (1972). Parasites of pond-raised *Clarias* in Thailand. *FAO Aquaculture Bulletin*, 5, 16-17.
- Arafa, S. Z., El-Naggar, M. M., & Kearn, G.C. (2003). Scanning electron microscope observations on the monogenean skin parasite *Macrogryodactylus congolensis* [Prudhoe, 1957] Yamaguti, 1963. *Acta Parasitologica*, 48(3):163-171.
- Arafa, S. Z., El-Naggar, M.M., & El-Abbassy, S.A. (2009). Mode of attachment and histopathological effects of *Macrogryodactylus clarii*, a monogenean gill parasite of the catfish *Clarias gariepinus*, with a report on host response. *Acta Parasitologica*, 54(2), 103-112.
- Bishai, H.M., & Khalil, M.T. (1997). Freshwater fishes of Egypt: Egyptian Environmental Affairs Agency. pp.577.
- Camargo, M.M., & Martinez, C.B. (2007). Histopathology of gills, kidney and liver of a Neotropical fish caged in an urban stream. *Neotropical Ichthyology*, 5(3), 327-336.
- Cone, D., & Odense, P. (1984). Pathology of five species of *Gyrodactylus* Nordmann, 1832 (Monogenea). *Canadian Journal of Zoology*, 62(6), 1084-1088.
- El-Naggar, A.M., & Reda, E.S. (2003). Infestation level and spatial distribution of *Protoanclodiscoides mansourensis* El-Naggar 1987, a monogenean gill parasite from the long fin catfish *Chrysichthys auratus* Geoffroy, 1809. *Egyptian Journal of Aquatic Biology and Fishery*, 7, 331-357.
- El-Naggar, M. M., Hagra, A. E., Ogawa, K., Hussein, A. B., & El-Naggar, A. M., (2001). Attachment of *Cichlidogyrus* monogenean species to the gills of the Nile fish *Oreochromis niloticus* and their local pathological impact on them. *Journal of Egyptian German Society of Zoology*, 35(D), 143-156.
- El-Naggar, M. M., & Kearn, G. C., (1989). Haptor glands in the gill-parasitic, ancyrocephaline monogenean *Cichlidogyrus halli typicus* and the report of a possible prokaryotic symbiont. *International Journal for Parasitology*, 19(4), 401-408.
- El-Naggar, M.M., & Serag, H.M., (1985). The monogenean *Quadriacanthus kearni* n. sp. and a report of *Q. clariadis clariadis* Paperna, 1979 on the gills of *Clarias lazera* in Nile Delta. *Journal of the Egyptian Society of Parasitology*, 15(2), 479-492.
- El-Naggar, M.M., & Serag, H. M. (1986). *Quadriacanthus aegypticus* n. sp., a monogenean gill parasite from the Egyptian teleost *Clarias lazera*. *Systematic Parasitology*, 8(2), 129-140.
- El-Naggar, M.M., Cable, J., Arafa, S. Z., El-Abbassy, S. A., & Kearn, G. C. (2016). Scanning and transmission electron microscopy of the histopathological impact of *Macrogryodactylus clarii* (Monogenea: Gyrodactylidae) on the gills of catfish, *Clarias gariepinus*. *Folia Parasitologica*, 63(017). doi: 10.14411/fp.2016.017.
- Evans, D.L., & Gratzek, J.B. (1989). Immune defense mechanisms in fish to protozoan and helminth infections. *American Zoologist*, 29(2), 409-418.
- Francová, K., Seifertová, M., Blažek, R., Gelnar, M., Mahmoud, Z.N., & Řehulková, E. (2017). *Quadriacanthus* species (Monogenea: Dactylogyridae) from catfishes (Teleostei: Siluriformes) in eastern Africa: new species, new records and first insights into interspecific genetic relationships. *Parasites and Vectors*, 10(1), 361. DOI 10.1186/s13071-017-2223-4
- Harris, P. (1983). The morphology and life-cycle of the oviparous *Oögyrodactylus farlowellae* gen. et sp. nov. (Monogenea, Gyrodactylidae). *Parasitology*, 87(3), 405-420.
- Hirazawa, N., Ishizuka, R., & Hagiwara, H. (2016). The effects of *Neobenedenia girellae* (Monogenea) infection on host amberjack *Seriola dumerili* (Carangidae): Hematological and histopathological analyses. *Aquaculture*, 461, 32-39.
- Kearn, G.C. (1998). Parasitism and the platyhelminths: Chapman & Hall Ltd. pp.xii + 544 pp.

- Lester, R. (1972). Attachment of *Gyrodactylus* to *Gasterosteus* and host response. *Journal of Parasitology*, 58(4), 717-722.
- Mansell, B., Powell, M., Ernst, I., & Nowak, B. F. (2005). Effects of the gill monogenean *Zeuxapta seriola* (Meserve, 1938) and treatment with hydrogen peroxide on pathophysiology of kingfish, *Seriola lalandi* Valenciennes, 1833. *Journal of Fish Diseases*, 28(5), 253-262.
- Molnár, K. (1972). Studies on gill parasitosis of the grass carp (*Ctenopharyngodon idella*) caused by *Dactylogyrus lamellatus* Achmerov, 1952. IV. Histopathological changes. *Acta Veterinaria Academiae Scientiarum Hungaricae*, 22(1), 9-24.
- Pahor-Filho, E., Castillo, A.S.C., Pereira, N. L., Pilarski, F., & Urbinati, E.C. (2017). Levamisole enhances the innate immune response and prevents increased cortisol levels in stressed pacu (*Piaractus mesopotamicus*). *Fish and Shellfish Immunology*, 65, 96-102.
- Paperna, I. (1980). Parasites infections and diseases of fish in Africa. FAO. *CIFA Technical paper*, 7, 7-23.
- Piasecki, W., Goodwin, A.E., Eiras, J.C., & Nowak, B.F. (2004). Importance of Copepoda in freshwater aquaculture. *Zoological Studies*, 43(2), 193-205.
- Ramadan, N., El-Banhawy, M., & Abdel Salam, M. (1995). Parasitological investigation on two monogenetic trematodes and their pathological impact on the grass carp *Ctenopharyngodon idella* in Egypt. *Journal of the Egyptian German Society of Zoology*, 17, 17-38.
- Rosety-Rodríguez, M., Ordoñez, F., Rosety, M., Rosety, J., Rosety, I., Ribelles, A., & Carrasco, C. (2002). Morpho-histochemical changes in the gills of turbot, *Scophthalmus maximus* L., induced by sodium dodecyl sulfate. *Ecotoxicology and Environmental Safety*, 51(3), 223-228.
- Schwaiger, J., Ferling, H., Mallow, U., Wintermayr, H., & Negele, R. (2004). Toxic effects of the non-steroidal anti-inflammatory drug diclofenac: Part I: histopathological alterations and bioaccumulation in rainbow trout. *Aquatic Toxicology*, 68(2), 141-150.
- Spotte, S.H. (1970). Fish and invertebrate culture: water management in closed systems. John Wiley & Sons, New York, 14, 145pp.
- Trujillo-González, A., Constantinoiu, C.C., Rowe, R., & Hutson, K.S. (2015). Tracking transparent monogenean parasites on fish from infection to maturity. *International Journal for Parasitology: Parasites and Wildlife*, 4(3), 316-322.
- Wilson, J.M., & Laurent, P. (2002). Fish gill morphology: inside out. *Journal of Experimental Zoology*, 293(3), 192-213.
- Zhao, X., Findly, R.C., & Dickerson, H.W. (2008). Cutaneous antibody-secreting cells and B cells in a teleost fish. *Developmental and Comparative Immunology*, 32(5), 500-508.